ISSN (Online): 3105-5346
ISSN (Print): 3105-5338

Journal of Pak International Medical College (JPIMC)

KNOWLEDGE | RESEARCH | BETTER HEALTHCARE

A Platform for Innovative Research in Medical Sciences

PAK INTERNATIONAL MEDICAL COLLEGE

Vol. 3, Issue 3 | July–September 2026

Open Access

ARTICLE METADATA

Article History

Received:	22 July 2026
Revised:	26 August 2026
Accepted:	20 September 2026
Published:	03 October 2026

Corresponding Author
Muhammad Hassan Nisar

Assistant Professor, ENT Department, Tertiary Care Hospital, Nishtar II, Multan

Email: hasannisar251@gmail.com

Keywords: Audiometry, Pure-Tone; Otitis Media; Ear Ossicles; Cholesteatoma; Tympanoplasty.

DOI: 10.64911/6d62cp40

Quick Response (QR) Code

Scan to read this article. on our website

Open Access

Original Article

Correlation of Pure-Tone Audiometry Findings with Middle Ear Pathology in Patients Undergoing Tympanomastoid Surgery

Rana Farrukh Tasleem[1], Sara Samad Qureshi[2], Muhammad Hassan Nisar[3], Muhammad Uzair Aslam[4], Muhammad Sharif Shahid[5], Amber Irfan[6]

1. Consultant. ENT Department, Indus Hospital Health Network, Recep Tayyip Erdogan Hospital, Multan
2. Senior Registrar, ENT Department, Tertiary Care Hospital, Nishtar II, Multan
3. Assistant Professor, ENT Department, Tertiary Care Hospital, Nishtar II, Multan
4. Audiologist, ENT Department, Indus Hospital Health Network, Recep Tayyip Erdogan Hospital, Multan
5. Assistant Professor, ENT Department, Nishtar Medical University, Multan
6. Senior Registrar, Department of Otorhinolaryngology, Ibn e Siena Hospital, Multan.

Abstract

Objective: To determine the correlation between preoperative pure-tone audiometry findings and intraoperative middle ear pathology in patients undergoing tympanomastoid surgery.

Methods: This analytical cross-sectional study included 120 adults with chronic otitis media who underwent tympanomastoid surgery between July 2025 and June 2026; we analyzed one operated ear per patient. We compared air-conduction and bone-conduction averages and the mean air–bone gap at 0.5, 1, 2, and 4 kHz across four ossicular mechanical categories. We used multivariable linear regression to adjust for clinical characteristics and assessed the diagnostic performance of an air–bone gap of at least 35 dB against operative ossicular discontinuity.

Results: Mean age was 35.82 ± 11.49 years, and 70 participants (58.3%) were men. We found discontinuity in 32 ears, fixation in 11, and cholesteatoma in 40. The mean air–bone gap was 24.12 ± 7.07 dB with an intact mobile chain, 37.45 ± 6.56 dB with discontinuity alone, and 33.54 ± 5.67 dB with fixation alone. After adjustment, discontinuity alone was associated with an 11.69 dB wider gap (95% CI 8.40–14.97). Perforation extent correlated with the air–bone gap (rho = 0.352), whereas disease duration showed no clear association with the bone-conduction average. The 35 dB threshold had a sensitivity of 75.0%, specificity of 86.4%, positive predictive value of 66.7%, and negative predictive value of 90.5%, missing 8 of 32 discontinuities.

Conclusion: Wider air–bone gaps were associated with ossicular discontinuity and fixation. Audiometry is useful for surgical preparation and counseling, but it does not reliably rule out an ossicular abnormality on its own.

How to Cite: **Tasleem RF, Qureshi SS, Nisar MH, Aslam MU, Shahid MS, Irfan A.** Correlation of Pure-Tone Audiometry Findings with Middle Ear Pathology in Patients Undergoing Tympanomastoid Surgery. Original Article.**J Pak Int Med Coll. 2026;3(3):245-251.**

© 2026 The Author(s) | This is an open access article distributed under the terms of the Creative Commons Attribution-NonCommercial 4.0 International License (CC BY-NC 4.0), which permits unrestricted use, distribution, and reproduction in any medium, provided the original work is properly cited and is not used for commercial purposes.

Introduction

Chronic otitis media is one of the most frequent reasons for middle ear surgery. Patients often live with recurrent ear discharge, hearing difficulty, and repeated treatment visits. In a Pakistani cohort, the size and site of tympanic membrane perforation were related to the degree of hearing loss [1], reminding us to assess hearing and visible anatomy together. When surgery is being considered, this information helps frame a realistic conversation with the patient about the source of the hearing loss. Pure-tone audiometry remains the most practical way to describe hearing before treatment. Air-conduction thresholds reflect both sound transmission through the middle ear and cochlear reserve, while bone-conduction thresholds characterize the sensorineural component. Audiometric profiles also vary with the clinical form of otitis media, so an audiogram has to be read in light of the underlying disease [2]. The link between audiometry and ossicular damage is of particular practical interest, because a surgeon who anticipates discontinuity can prepare for reconstruction. Maran and colleagues reported greater conductive loss with more extensive ossicular destruction [3], and Kadambott and colleagues found wider air–bone gaps in ears with eroded or absent ossicles than in ears with an intact chain [4]. A single threshold, however, cannot capture every mechanical problem. A larger surgical series assessed whether audiometry could predict both discontinuity and fixation, underlining that ossicular mobility matters as much as continuity [5]. Operative studies have also shown that mucosal and squamous disease damage the chain in different patterns, with the incus most often involved [6]. Cholesteatoma adds another layer of complexity, since disease clearance and hearing preservation must be balanced. Verma and colleagues observed more ossicular erosion in squamous than in mucosal disease [7]. Perforation size also affects hearing independently of ossicular damage, so it must be considered when interpreting the air–bone gap [8]. Bone-conduction thresholds add another dimension. Elevated thresholds have been reported in ears with mucosal disease, and age has been examined as a possible determinant of cochlear dysfunction [9]. When chronic otitis media with and without cholesteatoma was compared, differences in air conduction did not necessarily run parallel to differences in bone conduction [10]. These observations argue for reporting the conductive and sensorineural components separately.

In everyday practice, structural assessment complements functional testing. High-resolution computed tomography (CT) of the temporal bone has been evaluated for detecting tympanosclerosis and ossicular fixation [11], and a Pakistani study compared CT assessment of individual ossicles with operative findings, providing locally relevant evidence [12]. Otoendoscopic features associated with ossicular dysfunction in mucosal disease have also been described [13]. In mucosal disease, preoperative findings and disease duration have further been linked to operative observations and treatment outcomes [14]. Even so, the value of an audiogram for anticipating pathology must be tested in the surgical population in which it will be used. For surgeons working with limited resources, the practical question is whether routine hearing measurements add useful information before exploring the ear. A statistically significant association alone is not enough to support a diagnostic claim; the size of the adjusted difference, its uncertainty, and the number of misclassified ears matter just as much. The present study therefore compared preoperative audiometric findings with operative middle ear pathology in a tertiary care surgical population in Pakistan, with particular attention to ossicular discontinuity, fixation, cholesteatoma, and mucosal changes.

Material and Methods

This analytical cross-sectional study was conducted in tertiary care otorhinolaryngology settings in Pakistan between July 2025 and June 2026, and all records were pooled and analyzed as a single dataset. We compared preoperative audiometric function with the middle ear pathology documented at tympanomastoid surgery. We included one operated ear per participant; for bilateral disease, we selected the first eligible ear. The primary outcome was the mean air–bone gap, and operative ossicular mechanical status was the main explanatory variable. Each hospital's Institutional Review Board approved the study, and all participants provided written informed consent.Adults aged 18–68 years with chronic otitis media and a tympanic membrane perforation who underwent tympanoplasty with mastoid surgery were eligible. We included both mucosal disease and cholesteatoma, as well as ears with mixed hearing loss. We excluded patients who had previously

undergone surgery on the same ear or had a congenital ossicular anomaly, traumatic ossicular discontinuity, or external canal obstruction that prevented reliable audiometry. We fixed the sample size at 120 patients. We report precision with 95% confidence intervals, and we interpret estimates for small mechanical subgroups cautiously rather than assuming adequate power. Each participant was assigned a coded identifier, and the dataset contained no direct personal identifiers. Recorded variables included age, sex, disease duration, operated ear, presence of active discharge, perforation extent (percentage of the tympanic membrane involved), and the interval between audiometry and surgery. We linked clinical and audiometric data to the operative findings through the coded identifier. Before analysis, we checked the data for completeness and internal consistency, including agreement between the mechanical categories, the descriptors for individual ossicles, and the calculated hearing averages. We recorded air-conduction and bone-conduction thresholds in dB HL at 0.5, 1, 2, and 4 kHz in 5 dB steps. We calculated each conduction average as the arithmetic mean of these four thresholds, and the air–bone gap as the mean of the four frequency-matched air-minus-bone differences. We classified hearing loss as conductive when the bone-conduction average was 20 dB HL or less with an air–bone gap greater than 10 dB, and as mixed when the bone-conduction average exceeded 20 dB HL with an air–bone gap greater than 10 dB. Table 1 provides operational definitions.

Table 1. Operational definitions and analytical classifications

Variable	Definition
Air-conduction average	Mean threshold at 0.5, 1, 2, and 4 kHz (dB HL)
Bone-conduction average	Mean threshold at the same four frequencies (dB HL)
Mean air–bone gap	Mean of the four frequency-matched air-minus-bone differences (dB)
Discontinuity	Mechanical interruption of the ossicular chain
Fixation	Restricted ossicular mobility, with or without coexisting discontinuity
Mucosal inflammation	Granulation tissue, edematous mucosa, or both
Positive audiometric index	Mean air–bone gap ≥35 dB
Reference-positive status	Discontinuity, alone or combined with fixation

dB HL, decibels hearing level. Fixation is defined here as an operative finding; for analysis, ears were assigned to four mutually exclusive mechanical categories (see text). Other operative lesions could coexist.

At surgery, we recorded cholesteatoma, granulation tissue, edematous mucosa, and tympanosclerosis, along with the condition of each ossicle. We classified ossicular status into four mutually exclusive mechanical categories: intact mobile chain, discontinuity without fixation, fixation without discontinuity, and combined discontinuity with fixation. We recorded erosion separately from loss of continuity because an eroded ossicle may still be in continuity. We defined mucosal inflammation as granulation tissue, mucosal edema, or both, and distinguished tympanosclerosis involving the ossicular chain from disease limited to the tympanic membrane. Procedures were categorized as tympanoplasty with cortical mastoidectomy, canal wall up tympanomastoidectomy, or canal wall down tympanomastoidectomy. Analyses were performed in Python using NumPy, SciPy, and statsmodels. Continuous variables are reported as mean ± standard deviation (SD) or median (interquartile range, IQR), and categorical variables as counts and percentages. Groups were compared using Welch's analysis of variance (ANOVA), followed by pairwise Welch t-tests with Holm correction. We calculated Spearman correlation coefficients with bootstrap 95% confidence intervals based on 5,000 resamples. We used multivariable linear regression with HC3 robust standard errors to estimate adjusted differences in the air–bone gap, controlling for age, sex, perforation extent, disease duration, cholesteatoma, mucosal inflammation, and study site. We evaluated the diagnostic performance of the predefined 35 dB threshold against operative discontinuity, using Wilson 95% confidence intervals for proportions and log-method intervals for likelihood ratios. A sensitivity analysis excluded ears with combined lesions. We considered $p < 0.05$ statistically significant.

Results

All 120 participants (120 ears) were included in the analysis. Mean age was 35.82 ± 11.49 years (range 18–68), and 70 participants (58.3%) were men. We performed audiometry a median of 7 days before surgery. Measurements were complete for every participant, so all analyses used the full sample unless otherwise stated. Table 2 shows baseline characteristics and preoperative hearing levels.

Table 2. Participant characteristics and preoperative hearing measurements

Characteristic	Value
Age, years, mean ± SD	35.82 ± 11.49
Men/women, n (%)	70 (58.3) / 50 (41.7)
Disease duration, years, median (IQR)	5.55 (3.60–8.65)
Right / left operated ear, n (%)	71 (59.2) / 49 (40.8)
Active discharge, n (%)	48 (40.0)
Perforation extent, %, median (IQR)	45.00 (30.00–60.00)
Air-conduction average, dB HL, mean ± SD	40.34 ± 9.78
Bone-conduction average, dB HL, mean ± SD	12.02 ± 4.64
Mean air–bone gap, dB, mean ± SD	28.32 ± 9.26

N = 120. SD, standard deviation; IQR, interquartile range. We calculated hearing averages from four matched frequencies.

Figure 1 summarizes operative findings. The ossicular chain was intact and mobile in 82 ears (68.3%). We found discontinuity without fixation in 27 ears (22.5%), fixation without discontinuity in 6 (5.0%), and both together in 5 (4.2%). The incus was the most frequently eroded ossicle (38 ears, 31.7%), followed by the malleus (17 ears, 14.2%) and the stapes suprastructure (10 ears, 8.3%). Cholesteatoma was present in 40 ears (33.3%) and coexisted with mucosal inflammation in 28. Tympanosclerosis involved the ossicular chain in 9 ears and was confined to the tympanic membrane in 8. Erosion did not always interrupt the chain, which explains why the counts for individual ossicles differ from the mechanical categories.

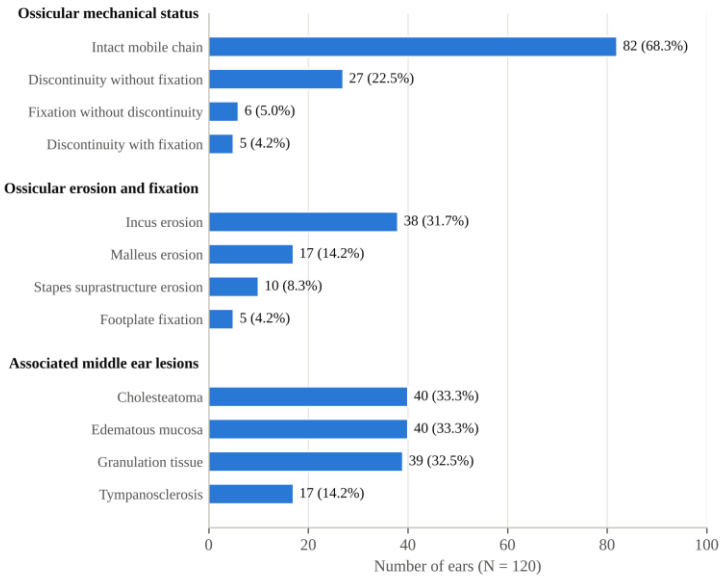

Figure 1. Operative middle ear findings in 120 ears. Values are the number of ears (%). The four ossicular mechanical categories are mutually exclusive; the remaining findings could coexist in the same ear. Figure 2 shows preoperative hearing levels by mechanical category. Compared with ears that had an intact mobile chain, the unadjusted mean air–bone gap was 13.34 dB wider with discontinuity alone (95% CI 10.35–16.32) and 9.43 dB wider with fixation alone (95% CI 3.50–15.36); both differences remained significant after Holm correction. The air-conduction average also differed across groups ($p < 0.001$), whereas the bone-conduction average did not ($p = 0.443$). The differences between groups therefore lay in the conductive component, while bone-conduction levels were similar regardless of ossicular status.

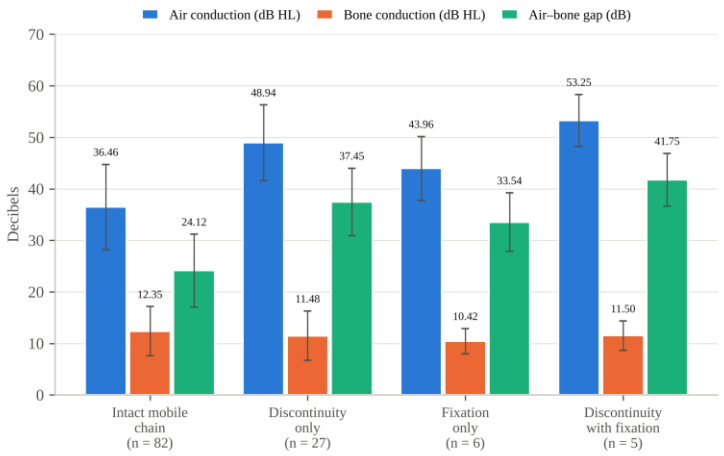

Figure 2. Preoperative air-conduction average, bone-conduction average, and mean air–bone gap by operative ossicular status. Bars show means and error bars show ±1 SD. Welch ANOVA: air conduction $p < 0.001$; bone conduction $p = 0.443$; air–bone gap $p < 0.001$. Holm-adjusted pairwise air–bone gap comparisons: discontinuity only vs intact chain $p < 0.001$; fixation only vs intact chain $p = 0.031$.Table 3 presents correlations and adjusted associations. A larger perforation was associated with a wider air–bone gap (rho = 0.352, $p < 0.001$), whereas disease duration showed no clear association with the bone-conduction average (rho = 0.055, $p = 0.548$). After adjustment, discontinuity alone, fixation alone, and combined abnormality remained associated with a wider gap of 11.69, 8.25, and 14.58 dB, respectively. Cholesteatoma added a smaller difference of 3.51 dB, and mucosal inflammation showed no clear independent association. The model explained 54.5% of the variation in the air–bone gap (adjusted $R^2 = 0.499$), and all 120 ears contributed to the estimates.

Table 3. Correlations and adjusted differences in the air–bone gap

Relationship or predictor	Estimate	95% CI	P
Perforation extent vs ABG, Spearman rho	0.352	0.181 to 0.504	<0.001
Disease duration vs BC, Spearman rho	0.055	−0.119 to 0.226	0.548
Discontinuity only, adjusted β (dB)	11.69	8.40 to 14.97	<0.001
Fixation only, adjusted β (dB)	8.25	2.58 to 13.91	0.005
Combined abnormality, adjusted β (dB)	14.58	9.72 to 19.43	<0.001
Cholesteatoma, adjusted β (dB)	3.51	0.22 to 6.80	0.037
Mucosal inflammation, adjusted β (dB)	−1.85	−4.53 to 0.83	0.173

Reference category for mechanical status: intact mobile chain. The model was also adjusted for age, sex, perforation extent, disease duration, and study site; confidence intervals for regression coefficients use HC3 robust standard errors. N = 120. ABG, air–bone gap; BC, bone-conduction average; CI, confidence interval.Table 4 summarizes diagnostic performance. The threshold produced 24 true positives, 12 false positives, 8 false negatives, and 76 true negatives, so 8 of the 32 ears with discontinuity were missed. When we excluded the five combined lesions, sensitivity fell to 70.4%, while specificity remained unchanged at 86.4%.

Table 4. Diagnostic performance of an air–bone gap of at least 35 dB for ossicular discontinuity

Measure	Estimate	95% CI
Sensitivity, %	75.0	57.9–86.7
Specificity, %	86.4	77.7–92.0
Positive predictive value, %	66.7	50.3–79.8
Negative predictive value, %	90.5	82.3–95.1
Positive likelihood ratio	5.50	3.13–9.65
Negative likelihood ratio	0.29	0.16–0.53

N = 120; prevalence of operative discontinuity 26.7%. Reference-positive status included discontinuity with or without fixation. Wilson intervals were used for proportions and log-method intervals for likelihood ratios.

Discussion

In this surgical cohort, both ossicular discontinuity and fixation were associated with a wider preoperative air–bone gap, and these associations held after adjustment for perforation extent and other

clinical features. The practical limitation is just as clear: the 35 dB threshold missed one in four discontinuities. Bhardwaj and colleagues found angled otoendoscopy to be more accurate than audiometry for predicting ossicular erosion [15]. Their findings align with the limited reassurance offered by a smaller gap here, and they support combining functional and anatomical assessment. The adjusted estimates suggest that mechanical status carries information beyond the routinely recorded disease descriptors. Gupta and colleagues used the Middle Ear Risk Index to relate several disease characteristics to tympanomastoid surgery outcomes [16], and Jung and colleagues identified middle ear conditions that influenced ossiculoplasty outcomes in patients with severe-to-profound hearing loss [17]. Both studies support a broad preoperative assessment, although neither directly validates the threshold examined here. Differences between mechanical groups were evident in air conduction but not in bone conduction, consistent with a predominantly conductive effect of ossicular disease. Al Hamoud and colleagues, who evaluated hearing around tympanoplasty together with operative ossicular status, provide a useful clinical comparison [18]. The distinction between tympanosclerosis confined to the membrane and that involving the ossicles also matters. Ghosh described separate patterns affecting the membrane, the ossicles, and the footplate [19], which explains why a sclerotic plaque alone does not predict a particular hearing deficit. Fixation was associated with an adjusted 8.25 dB increase in the air–bone gap even though the chain was continuous in the fixation-only group. Yildiz and colleagues examined CT predictors of ossicular fixation in tympanosclerosis, showing the value of imaging when mobility is in doubt [20]. Özdek's results after endoscopic management of tympanosclerosis similarly highlight the difference between a chain that is anatomically continuous and one that transmits sound effectively [21]. Therefore, document mobility separately from erosion and discontinuity. These findings support counseling patients about possible ossicular reconstruction, without promising a specific postoperative gain. Alosaimi and colleagues compared tympanoplasty with and without ossiculoplasty [22], and Fink and colleagues reported multicenter outcomes after endoscopic ossiculoplasty [23]. Both studies measured hearing after surgery, which the present cross-sectional design did not. Their results can inform discussion of reconstructive options, but they cannot establish the likely benefit in this population. Systematic reviews by Lewis and colleagues on hearing restoration in chronic otitis media [24] and by Poupore and colleagues on tympanoplasty with or without mastoidectomy in non-cholesteatomatous disease [25] assessed treatment effectiveness across varied populations. They reinforce the need to separate a preoperative association from eventual recovery: a wider gap does not, by itself, determine the most appropriate operation or guarantee a meaningful improvement in hearing after reconstruction. This study has several strengths. Operative findings served as the reference standard, and we had complete audiometric and surgical data for all 120 participants. We frequency-matched hearing averages, classified ossicular continuity and mobility separately, and defined the 35 dB threshold in advance. We adjusted for key clinical factors using robust standard errors, and a sensitivity analysis excluding combined lesions tested the stability of the diagnostic estimates. The main limitations are the small fixation and combined-lesion subgroups and the lack of postoperative follow-up. The 35 dB threshold should also be validated in an independent sample.

Conclusion

Preoperative air–bone gaps were wider in ears with ossicular discontinuity and fixation, and these associations persisted after adjustment for perforation extent, cholesteatoma, and other clinical characteristics. A gap of 35 dB or more should raise suspicion of discontinuity, but it missed one in four affected ears. Audiometry is therefore best used alongside anatomical assessment to guide counseling and preparation for reconstruction. Interpret findings for the small fixation and combined-lesion groups with caution.

Ethical Approval

The Institutional Ethical Review Board (IERB), Nishtar Medical University, Multan, Pakistan, approved this **study (Ref. No. 221/25; dated 2 December 2025).**

Funding

This study received no specific funding from any public, commercial, or not-for-profit funding agency.

Conflict of Interest

The authors declare no competing interests or conflicts of interest related to this study.

Authors' Contributions

Rana Farrukh Tasleem: Conceptualization, clinical investigation, data collection, and manuscript review.

Sara Samad Qureshi: Data collection, clinical investigation, and manuscript drafting.

Muhammad Hassan Nisar: Conceptualization, supervision, methodology, clinical investigation, and critical revision of the manuscript.

Muhammad Uzair Aslam: Audiometric assessment, data collection, and data curation.

Muhammad Sharif Shahid: Clinical supervision, surgical investigation, and critical review of the manuscript.

Amber Irfan: Clinical investigation, data collection, and manuscript review.

References

1. Khurshid N, Khurshied S, Khizer MA, Hussain A, Safoor I, Jamal A. Relationship of hearing loss and tympanic membrane perforation characteristics in chronic suppurative otitis media patients. Cureus. 2022;14(12):e32496. doi.org/10.7759/cureus.32496.

2. Araújo ALPK, Cordeiro FP, da Costa Monsanto R, Penido NO. Audiometric evaluation in different clinical presentations of otitis media. Braz J Otorhinolaryngol. 2024;90(1):101359. doi.org/10.1016/j.bjorl.2023.101359.

3. Maran R, Meena K, George SP. Correlation between pure tone audiometry values and middle ear ossicular chain status in chronic otitis media: study in a tertiary health care center. Indian J Otolaryngol Head Neck Surg. 2024;76(3):2684-9. doi.org/10.1007/s12070-024-04557-3.

4. Kadambott S, Kumar Gure P, Ghatak S, Dutta M, Seth C, Das S, et al. How does preoperative pure-tone audiometry relate to the findings at surgery to explain hearing status in chronic otitis media? Medeni Med J. 2023;38(1):16-23. doi.org/10.4274/MMJ.galenos.2023.30509.

5. Faramarzi M, Kazemi T, Roosta S, Faramarzi A, Naghmachi M. Is pre-operative audiometry a reliable predictor of ossicular chain condition? Am J Otolaryngol. 2023;44(5):103928. doi.org/10.1016/j.amjoto.2023.103928.

6. Rana A, Satpute SS, Singh M, Arora RD, Nagarkar NM. Intraoperative ossicular chain status in patients with chronic otitis media. Indian J Otolaryngol Head Neck Surg. 2024;76(3):2564-9. doi.org/10.1007/s12070-024-04553-7.

7. Verma RB, Kumar R, Kapadia PB, Panchal AJ, Sheth S. Intra-operative ossicular chain status in patients with chronic otitis media. Indian J Otolaryngol Head Neck Surg. 2024;76(2):1563-8. doi.org/10.1007/s12070-023-04360-6.

8. Begh RA, Kishore K, Kalsotra G, Saraf A, Kalsotra P. Impact of site, size and duration of tympanic membrane perforation on hearing loss and postsurgical outcome. Indian J Otolaryngol Head Neck Surg. 2022;74(Suppl 1):S699-706. doi.org/10.1007/s12070-021-02487-y.

9. Philipose R, Varghese A, Kumar N, Varghese SS. Determinants of cochlear dysfunction in chronic otitis media: mucosal disease. Indian J Otolaryngol Head Neck Surg. 2023;75(4):3733-8. doi.org/10.1007/s12070-023-04093-6.

10. Tang Y, Lian B, Zhang M, Tu X, Zhang T, Wang H. Sensorineural damage in chronic suppurative otitis media with and without cholesteatoma: a comparative study. Ann Transl Med. 2022;10(14):778. doi.org/10.21037/atm-22-2606.

11. Larem A, Abu Rajab Altamimi Z, Aljariri AA, Haidar H, Elsotouhy A, Alsaadi A, et al. Reliability of high-resolution CT scan in diagnosis of ossicular tympanosclerosis. Laryngoscope Investig Otolaryngol. 2021;6(3):540-8. doi.org/10.1002/lio2.594.

12. Altaf J, Ashfaq AH, Arshad M, Riaz N, Shabbir Z, Mughal HH, et al. Diagnostic accuracy of plain computed tomography of the temporal bone in detection of pre-operative ossicular status versus per-operative findings in chronic otitis media. Indian J Otolaryngol Head Neck Surg. 2024;76(3):2601-7. DOI not independently verified; verify against the original publication before submission.

13. Mannuru KB, Havle AD, Vihapure GM, Shedge SA, Prabhune SC, Ahmed K, et al. Otoendoscopy and audiometry findings as predictors of ossicular dysfunction in mucosal chronic suppurative otitis media: a cohort study. J Clin Diagn Res. 2021;15(12):MC01-4. doi.org/10.7860/JCDR/2021/49481.15775.

14. Sunny FA, Nalamate R, Chandran S, Kumar P, Kurien M. Mucosal-type chronic otitis media: clinical predictors of postoperative success. Cureus. 2024;16(3):e56213. doi.org/10.7759/cureus.56213.

15. Bhardwaj A, Gupta K, Suji PS, Malhotra M, Priya M, Varshney S, et al. Otoendoscopy as a better preoperative predictor than pure tone audiometry for ossicular erosion in mucosal chronic otitis media. J Laryngol Otol. 2024;138(10):1013-7. doi.org/10.1017/S002221512400080X.

16. Gupta MC, Sharma S, Rajpurohit P, Aseri Y, Verma PC. A prospective study on correlation of MERI (Middle Ear Risk Index) score with surgical outcome of tympano-mastoid surgery in patients with CSOM. Indian J Otolaryngol Head Neck Surg. 2023;75(Suppl 1):S216-21. doi.org/10.1007/s12070-022-03320-w.

17. Jung DJ, Son J, Kwon HG, Kwon E, Lee KY. Efficacy of ossiculoplasty in patients with chronic otitis media with severe to profound hearing loss. Sci Rep. 2025;15(1):4974. doi.org/10.1038/s41598-024-84966-0.

18. Al Hamoud M, Alzubaidi A, Al Shahrani K, Alotaibi G, Alkenani FA, Alahmari Y, et al. Degree of hearing improvement and reduction of air-bone gap after tympanoplasty in a tertiary hospital in Saudi Arabia. Cureus. 2024;16(2):e55159. doi.org/10.7759/cureus.55159.

19. Ghosh A. Monograph on tympanosclerosis-clinico-pathological correlation and surgical outcome: a retrospective study. Indian J Otolaryngol Head Neck Surg. 2022;74(Suppl 3):S4059-64.

20. Yildiz S, Balık AÖ, Zer Toros S. Is ossicular chain fixation predictable for tympanosclerosis on preoperative temporal bone computed tomography? Eur Arch Otorhinolaryngol. 2021;278(8):2789-94. doi.org/10.1007/s00405-020-06365-1.

21. Özdek A. Endoscopic transcanal management of tympanosclerosis. Eur Arch Otorhinolaryngol. 2022;279(2):677-83. doi.org/10.1007/s00405-021-06692-x.

22. Alosaimi A, Abulfateh FN, Bedawi FK, Aljeeb AM, Sabra OA. Comparison of hearing outcomes in tympanoplasty with and without ossiculoplasty: a retrospective cohort study. Cureus. 2024;16(11):e73924. doi.org/10.7759/cureus.73924.

23. Fink R, Molinari G, Burato A, Stricker D, Bisi N, Marchioni D, et al. Endoscopic ossiculoplasty: audiological and surgical outcomes from a multicenter experience with 292 cases. Eur Arch Otorhinolaryngol. 2025;282(11):5571-80. doi.org/10.1007/s00405-025-09473-y.

24. Lewis A, Vanaelst B, Hua H, Choi BY, Jaramillo R, Kong K, et al. Success rates in restoring hearing loss in patients with chronic otitis media: a systematic review. Laryngoscope Investig Otolaryngol. 2021;6(3):522-30. doi.org/10.1002/lio2.576.

25. Poupore NS, Gordis TM, Nguyen SA, Meyer TA, Carroll WW, Lambert PR. Tympanoplasty with and without mastoidectomy for chronic otitis media without cholesteatoma: a systematic review and meta-analysis. Otol Neurotol. 2022;43(8):864-73. doi.org/10.1097/MAO.0000000000003631.